
Surgical Technical Report

Primary Repair is Possible in Complete Sternal Cleft: The First Saudi Experience

Husain H. Jabbad, FRCSC

*Department of Cardiothoracic Surgery, Faculty of Medicine
King Abdulaziz University, Jeddah, Saudi Arabia
hjabbad@gmail.com*

Abstract. A report of a successful primary repair of a congenital complete sternal cleft in an adult using titanium plates fixed by predrilled screws to the manubrium and costal cartilages. This provided an excellent protective and cosmetic result. To our knowledge, this is the first Saudi case report in literature.

Keywords: Sternum, Cleft, Titanium plates.

Introduction

Congenital sternal fissure or cleft is a very rare anomaly, accounting for less than 1 in 100,000 live births. It results from failure of ventral fusion of the sternum which occurs in about on the 8th week of gestation. The complete type occurs in only about 20% where bone formation is absent between the hyoid and the pubis^[1-3]. The ideal time for repair is in infancy, as soon as the defect is discovered. Later on, the repair becomes more difficult and complicated requiring complex prosthetic material.

Case Presentation

A 35-years-old female was presented with complete sternal cleft since birth, causing a cosmetic concern and constant fear of trauma. Physical examination showed visible aortic and cardiac pulsations.

Correspondence & reprint request to: Dr. Husain Jabbad

P.O. Box 80215, Jeddah 21589, Saudi Arabia

Accepted for publication: 20 January 2010. Received: 14 June 2009.

There was a complete sternal cleft which measured 6 cm width between the remnants of the sternal edges in inspiration and 4cm in expiration with divarication of the recti. During Valsalva maneuver the sternal cleft became wider and the heart bulge was more prominent. No other congenital anomalies apart from hypothyroidism discovered and treated since early childhood. Echocardiography showed no congenital defects. Computerized tomograms were done and confirmed the diagnosis (Fig. 1 and 2). The laboratory investigations were all within normal limits. Intraoperatively, the mediastinal tissues covering the pericardium were

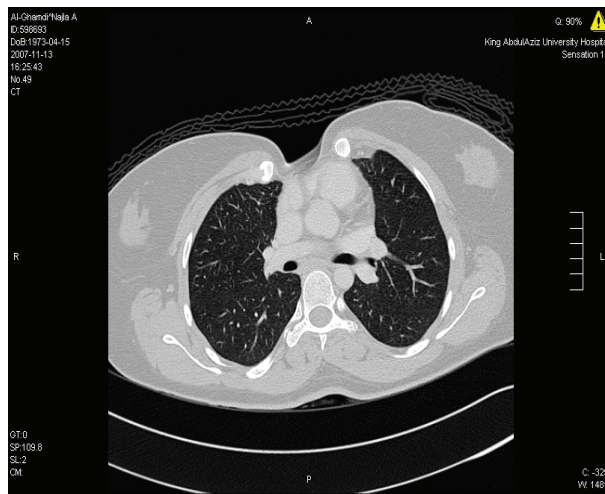


Fig. 1. 3D computerized tomography reconstruction shows the complete sternal cleft.

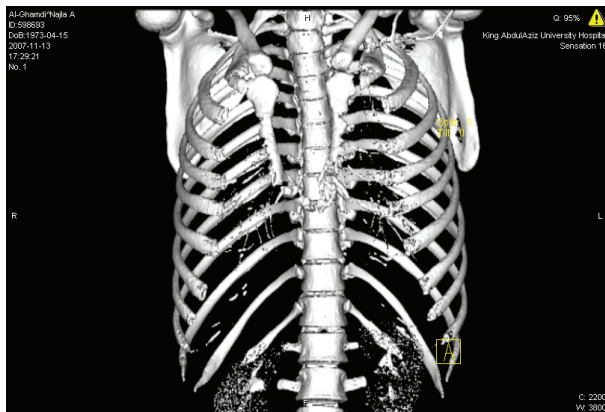


Fig. 2. Computerized tomography shows the coronal section of the cleft.

carefully dissected to expose the anterior and posterior aspect of the sternal body edges. Subcutaneous skin flaps were raised on both sides to expose the manubrial ends and the upper four costal cartilages along with ribs. The under surface of the sternum and ribs were also mobilized. The first trial of test approximation of the sternal edges resulted in signs of cardiac compression. Widely opening the left pleural cavity and second trial of gradual plus a slow approximation did not show any hemodynamic changes.

The sternal fixation system using titanium plates was chosen because of its ideal application in such cases with deficient sternal bone. The length the screws were selected according to the sternal thickness. A star shaped titanium plate was used in the manubrium and two rows were applied to the third and fourth costal cartilages. Each plate on either side was fixed with multiple screws at predrilled sites (Fig. 3a, Fig. 3b). Postoperative course was smooth and the patient was discharged home well. The patient has been followed for more than one year with excellent results and full patient satisfaction.

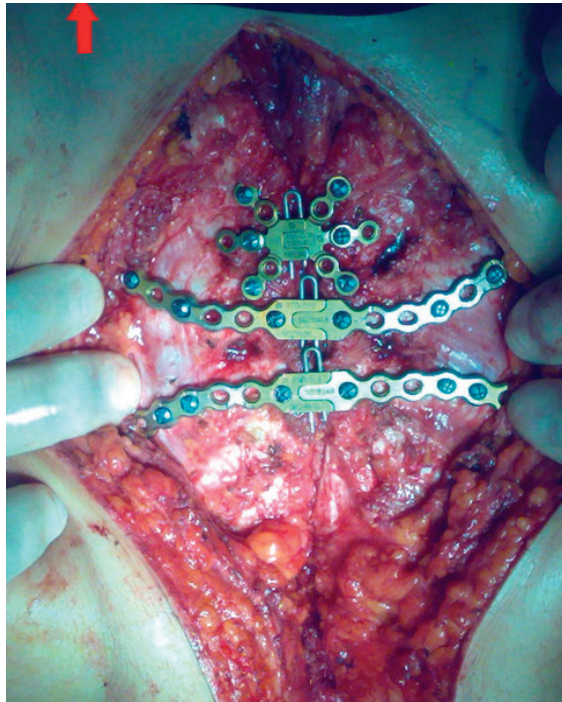


Fig. 3 (a). Intraoperative picture of the the titanium plate system.

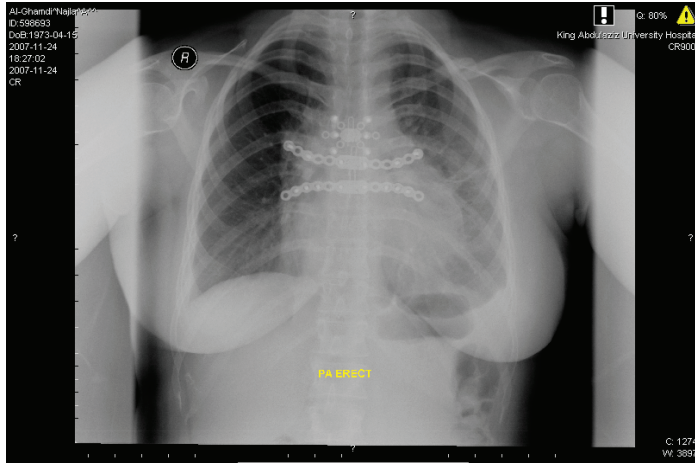


Fig. 3 (b). Post operative chest X-ray showing the titanium plate system.

Discussion

Few cases have been reported in the literature and most of them were partial clefts repaired in the neonatal period, which is the ideal time where the chest wall and thoracic cavity are still elastic and flexible. Most of the difficulty of closing these clefts in adults is attributed the rigidity of the chest wall and lack of the flexibility.

Sternal clefts, especially the complete one have to be closed for protection of the heart and great vessels as those patients feel insecure in addition to the cosmetic appearance. Our patient is the oldest age of presentation of such defects.

The sternal fixation system using plates is ideal for those patients as there is not enough sternal bone to use stainless steel wires. This system has been used in patients with mediastinitis and complicated sterna dehiscence instead of the conventional closure which proved to be effective^[4]. The other advantage of this system is its locking and unlocking feature which allow easy opening in re-exploration. The width of the cleft is the most important factor determining the possibility of direct closure.

In our case it was about 6 cm in inspiration which is considered a fairly wide space and perhaps, the gradual closure plus opening the left pleural cavity helped in avoiding cardiac compression. The availability of sternal substitute reconstructive procedure has to be there at all times

in case of intolerance to direct closure. All reported cases in the literature of complete cleft repair were done using either synthetic Marlex, Teflon or Prolene Mesh, methacrylate sandwich or autogenous tissues (iliac crest or rib grafts) covered by pectoralis major myocutaneous flaps^[5-8]. The main drawbacks and hazards of such complex sternal reconstruction is the huge amount of foreign body material with its liability to untoward reaction, such as infection, extra weight on the sternum and the difficulty of going back to the heart, or other mediastinal structures for any surgical procedure in the future.

Santini *et al.* reported a successful primary repair of complete sternal defect associated with congenital heart disease^[7]. Sarper and colleagues reported sternal reconstruction using pectoralis muscle flaps in a 13 years old girl with complete cleft and pectus excavatum^[8]. Our patient is the rarest subtype of an unusual chest wall defect and late age of presentation. In conclusion, simple sternal closure should be attempted in those patients before embarking on a complex reconstruction with all its drawbacks.

References

- [1] **Ravitch MM.** Disorder of the sternum and the thoracic wall. In: Gibbon's Surgery of the Chest. Sabiston DC Jr, Spencer FC, eds., 4th ed. Philadelphia: Saunders, 1983. 318-360.
- [2] **Sabiston DC Jr.** The surgical management of congenital bifid sternum with partial ectopia cordis. *J Thorac Surg* 1958; **35**(1): 118-122.
- [3] **de Campos JR, Filomeno LT, Fernandez A, Ruiz RL, Minamoto H, Werebe Ede C, Jatene FB.** Repair of congenital sternal cleft in infants and adolescents. *Ann Thorac Surg* 1998; **66**(4): 1151-1154.
- [4] **Voss B, Bauernschmitt R, Will A, Krane M, Kröss R, Brockmann G, Libera P, Lange R.** Sternal reconstruction with titanium plates in complicated sternal dehiscence. *Eur J Cardiothorac Surg* 2008; **34**(1): 139-145.
- [5] **Snyder BJ, Robbins RC, Ramos D.** Primary repair of complete sternal cleft with pectoralis major muscle flaps. *Ann Thorac Surg* 1996; **61**(3): 983-984.
- [6] **Suri RK, Sharma RK, Jha NK, Sharma BK.** Complete congenital sternal cleft in an adult: repair by autogenous tissues. *Ann Thorac Surg* 1996; **62**(2): 573-575.
- [7] **Santini F, Faggian G, Pessotto R, Mazzucco A.** Successful repair of complete sternal cleft associated with congenital heart disease. Report of one case. *J Cardiovasc Surg (Torino)* 1995; **36**(1): 75-77.
- [8] **Sarper A, Oz N, Arslan G, Demircan A.** Complete congenital sternal cleft associated with pectus excavatum. *Tex Heart Inst J* 2002; **29**(3): 206-209.

إصلاح جراحي ناجح لشق خلقي كامل بعظمة القص في الكبار: أول خبرة سعودية

حسين حمزة جباد

وحدة جراحة القلب، كلية الطب، جامعة الملك عبد العزيز
جدة - المملكة العربية السعودية

المستخلص. نوضح هنا إصلاح أولي ناجح لشق خلقي كامل بعظمة
القص في الكبار باستخدام شرائح تيتانيوم مثبتة بمسامير بعظمة
القص وعضاريف الصدر مما أعطى نتائج حماية وتجميلية ممتازة.